

Periimplantitis

Himanshu Khashu, CS Baiju, Gunjan Gupta, Praful Bali

ABSTRACT

Periimplantitis is an inflammatory process that affects both the hard and soft tissues around a functional implant and results in marginal bone loss, which may eventually lead to loss of osseointegration. Bacterial infection is known to play a major role in the etiology of this disease although there remains some debate as to whether this is a host susceptibility related or implant surface phenomenon or both. Prevention of these infections is a major factor when treating patients with implants, particularly, if they present with a periodontal disease. This article presents the etiology, pathogenesis and treatment of periimplantitis that has been seen to yield favorable results.

Keywords: Microbiota, Periimplantitis, Peri-mucositis, Periodontitis, Lasers.

How to cite this article: Khashu H, Baiju CS, Gupta G, Bali P. Periimplantitis. *Int J Oral Implantol Clin Res* 2012;3(2):71-76.

Source of support: Nil

Conflict of interest: None declared

INTRODUCTION

Endosseous oral implants have successfully been used during the last decades for facilitating the replacement of missing teeth in totally or partially edentulous patients. Although considered a highly successful treatment modality, concerns have been raised in the literature regarding local infectious conditions in conjunction with oral implants. Infection around implants has been described and named as periimplantitis.¹

Periimplantitis is defined as an inflammatory reaction with the loss of supporting bone in the tissues surrounding a functioning implant.²

Periimplantitis denotes an inflammatory reaction affecting the tissues surrounding osseointegrated dental implants resulting in loss of supporting bone. Periimplantitis has also been described as a site-specific infection yielding many features in common with chronic adult periodontitis.³

Healthy Periodontium around Implants

During the past decade, the demand for dental implants, artificial tooth roots has grown considerably. Dental implants are used to replace removable partial or full dentures in edentulous and partially edentulous patients. Implants and implant-supported prostheses offer greater stability, comfort and esthetics than any other removable prostheses. Dental implants are titanium fixtures placed into the jaw bone during surgery. Titanium is the most common

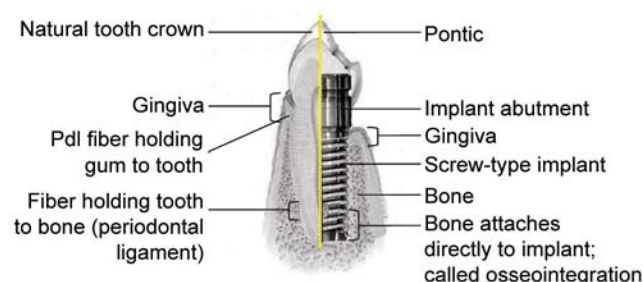


Fig. 1: Basic comparison model—implant versus tooth

biometal used in endosseous dental implants because of its excellent biocompatibility property in physiological conditions.⁴

The term osseointegration means direct bone contact with an alloplastic metallic implant. The hard and soft tissues surrounding an osseointegrated implant show some similarities to the periodontium around natural dentition (Fig. 1).⁵ The gingiva around dental implants is called periimplant mucosa, and consists of well-keratinized oral epithelium, sulcular epithelium and junctional epithelium with underlying connective tissue. Between the implant surface and epithelial cells are hemidesmosomes and the basal lamina.⁶ The most significant difference between natural teeth and implants is that implants lack the periodontal ligament. The collagen fibers are unattached and parallel to the implant surface rather than in functional contact from the bone to the cementum. The titanium screw attaches directly to the alveolar bone, which is in direct and tight contact with the implant surface.

Classification and Pathogenesis of Periimplantitis

Periimplantitis is regarded as an 'infection-induced inflammatory process affecting the tissues around an osseointegrated implant in function, resulting in loss of supporting bone'.²

Although dental implant therapy has been considered to have an excellent prognosis, recent reports on the long-term success of implant therapy have presented surprisingly high prevalence rates of perimucositis and periimplantitis.⁷

A number of risk factors have been identified, including (1) poor oral hygiene, (2) a history of periodontitis, (3) diabetes and (4) smoking.⁸

Two types of implant failures have been identified and should be considered separately as follows:

- I. An early implant failure due to occlusal overloading corresponds to the inability to establish osseointegration.⁹ Occlusal overload increases the risk for microfractures

at the implant-bone interface which can result in significant marginal bone loss and implant failure.¹⁰

II. A late implant failure is periimplantitis, a site-specific inflammatory disease with microorganisms associated in patterns known from the chronic periodontitis of natural teeth, leading to bone loss and finally to implant failure.¹¹ The microbial plaque accumulation is considered the most important factor in the pathogenesis of periimplantitis.¹² In the initial stage, plaque accumulation can cause perimucositis, a reversible inflammation of the soft tissues surrounding functional implants.¹³ The adherence of microorganisms to nonshedding biomaterial surfaces and the successful colonization of these surfaces are principal factors in biomaterial-associated infections.¹⁴ The periimplant microflora is established shortly after implant placement, and several studies have demonstrated that periodontal pathogens, such as *P. intermedia*, can be transmitted from residual teeth to implants.¹¹ Overall, microbiota found in periimplant lesions is similar or at least almost similar to that found in periodontal lesions.¹⁵ Distinct from periodontitis, spirochetes are closely linked to periimplantitis. Structurally, the periimplant epithelium closely resembles the junctional epithelium found around natural teeth. The periimplant epithelium produces inflammatory mediators, and the local host response is biochemically similar to the response observed in periodontitis.¹⁶

Failing implants affected by periimplantitis are generally characterized by:

1. The presence of mobility.
2. Progressive marginal bone loss resulting in a typical 'crater-like' bony defect, while the bottom part of the implant retains perfect osseointegration.
3. Signs of infection and inflammation, the infiltration of inflammatory cells, plasma cells and PMNs, and the ulceration and proliferation of the junctional epithelium.

MICROORGANISMS IN HEALTHY AND DISEASED PERIIMPLANT SITES

Healthy periimplant sites are characterized by high proportions of coccoid cells, a low ratio of anaerobic/aerobic species, a low level of Gram-negative species, and low detection frequencies of periodontal pathogens.^{11,17-19} Implants with periimplantitis reveal a complex microbiota encompassing conventional periodontal pathogens species, such as *Aggregatibacter actinomycetemcomitans*, *Porphyromonas gingivalis*, *Tannerella forsythia*, *Peptostreptococcus micros*, *Campylobacter rectus* and *Fusobacterium* species.^{11,20} Other more unusual oral species,

such as *Pseudomonas aeruginosa*, *Enterobacteriaceae*, *Candida albicans* and Staphylococci can also be recovered from failing implants.²¹

DIAGNOSIS OF PERIIMPLANT TISSUE BREAKDOWN

Periimplant Probing

To diagnose a compromised implant site, soft tissue measurements using manual or automated probes have been suggested. Probing the periimplant sulcus with a straight periodontal probe allows assessment of the following parameters:

- Periimplant probing depth.
- Distance between the soft tissue margin and a reference point on the implant (measure of soft tissue hyperplasia or recession).
- Bleeding after probing.
- Exudation and suppuration from the periimplant space.
- Successful implants generally allow probe penetration of approximately 3 mm.
- For teeth, a probing force of 0.25 N has been recommended (Lang et al 1991). It appears reasonable to use the same probing force for determination of bleeding on probing around implants.
- Probing depth measurements related to fixed landmark on the implant and examination of the bleeding tendency of the periimplant tissues seem to be well-suited for the longitudinal monitoring of periimplant stability. Standardized probes, such as the Audio probe, the TPS probe or the HAWE Click probe, may be recommended.

Mobility

- Implant mobility is an indication for lack of osseointegration. Even if disease conditions in the periimplant tissues have progressed relatively far, implants may still appear immobile due to some remaining direct bone to implant contact.
- Thus, mobility is insensitive in detecting the early stages of periimplant disease.
- The parameter serves to diagnose the final stage of osseodisintegration and may help to decide that an implant has to be removed.
- For interpretation of low degrees of mobility an electronic device has been designed to measure the damping characteristics of the periodontium of natural teeth—periotest.

- Periotest readings were found to be related to characteristic of the mandible, the periimplant tissue and the length of the abutment.
- The prognostic value of periotest readings for periimplantitis remains to be determined.
- Radiographic examination cannot be the only parameter to estimate the performance of implants in the individual patient.
- In absence of clinical signs of infection, it is recommended to take radiographs 1 year after implant installation and every other year thereafter.

Suppuration

- Histologic examinations of periodontal tissues show an infiltration with neutrophils whenever disease is present.
- High numbers of leukocytes have been shown also with implants that have increased gingival inflammation.
- Suppuration is associated with disease activity and indicates a need for antiinfective therapy.

Clinical Indices

- Swelling and redness of the marginal tissues have been reported form periimplant infections in addition to pocket formation, suppuration and bleeding.
- Recognition of these signs has been considered important in the diagnosis of periodontal disease.
- Parameters developed for teeth are not strictly applicable to the features of tissues encountered around implants.
- The bleeding tendency of the marginal periimplant tissues can be assessed using the modified sulcus index.
- An index for assessing periimplant mucosal tissues based on the gingival index, but without incorporating the bleeding criterion, has also been proposed.
- Scorings from teeth and implants should be handled and interpreted separately.
- The texture and color of the tissues which are important discriminators between gingival index scores depend on the normal appearance of the recipient tissues before implantation and vary due to properties of the implant surface.
- The modified plaque index may be used to assess the amount of plaque on implants.

Periimplant Radiography

- Vertical bone loss of less than 0.2 mm annually following the implants first year of service has been proposed as one of the major criteria for success.
- For accurate assessments of bone level changes, longitudinal series of standardized radiographs are required.
- Detection of minute changes of bone level or density requires reproducible projection geometry for the X-ray beam, provided by an appropriate aiming device.
- Above-mentioned changes in the range of 0.1 mm are only mathematically determined and cannot be detected by comparison of two radiographs from a single implant.

Microbiology

- Bacterial culture, DNA probes, polymerase chain reaction, monoclonal antibody and enzyme assays to monitor the subgingival flora have been proposed to determine an elevated risk for periodontal disease or periimplantitis.
- Studies indicating the existence of different forms of periimplant disease, including specific infections and nonbacterial failures illustrate that microbiological tests may be valuable tools for the differential diagnosis of periimplantitis and for planning treatment.

Clinical Appearance of Periimplantitis⁸

Periimplantitis lesions are often asymptomatic and usually detected at routine recall appointments. Careful probing around teeth and implants should be routine procedures included at these check-up appointments. The validity of probing around implants to properly detect periimplant lesions has previously been questioned, although this dogma needs to be reassessed. Increased clinical probing pocket depth, often accompanied by bleeding and sometimes suppuration, is an indicator of pathology in periimplant tissues. A common clinical problem regarding probing at implants is accessibility (i.e. the design of the bridgework may interfere with the probing procedure). In this context, it is important to realize that periimplant defects normally encompass the full circumference of the implant; therefore, it may be sufficient to probe only solitary sites at any given implant when there is obstruction by the prostheses. Based on the findings of the clinical examination, radiographs of the selected areas may be proposed. In periimplantitis, a bony defect develops around single or multiple implants. The radiographic appearance is often in the shape of a saucer or rounded beaker and, as stated earlier, the lesion most often extends the full circumference of the implant. Periimplant lesions may develop after several years. In biomedicine, a 'safety zone' of 5 years has often been misinterpreted to denote safe survival or no further risk for disease progression. In periodontitis, tissue destruction seems to be a relatively slow process; consequently, a function time exceeding 5 years for implants may be required to detect destructive periimplantitis sites. Regular check-up visits and life-long supportive therapy is an absolute necessity for the implant patient.

TREATMENT OF PERIIMPLANTITIS

Historically, periimplantitis has been associated with macro-rough, porous coatings, such as titanium plasma spray and hydroxyapatite, which saw a very aggressive form of infection with rapid bone loss leading to implant failure. In contrast, implants with a microroughened surface texture have presented excellent long-term data^{22,23} and until recently there has been very little published in the literature demonstrating a susceptibility of these surfaces to this condition. However, the application of implants in the partially dentate patient is unquestionably leading to higher incidences of cross-infection of periimplant sites.^{24,25}

While the use of lasers has been extensively reported,²⁶⁻²⁹ this methodology remains outside the reach of most general practitioners and much attention remains focused on physical debridement and antimicrobial therapy. To this end the topical use of tetracyclines remains a firm favorite, not least because they chelate to hydroxyapatite in bone from where they can mediate their effect.³⁰

The following surgical protocol has proven reliable and predictable in the treatment of advanced periimplantitis lesions:

1. Systemic antibiotics equivalent to metronidazole 400 mg TDS for three days preoperatively.
2. Preoperative 1 minute mouthwash with 0.2% chlorhexidine.
3. Full thickness flap elevation extending beyond the infected area to sound tissues.
4. Comprehensive debridement and curettage down to fresh bone, including mechanical curettage of implant surface with carbon fiber curettes.
5. Pack gauze strips soaked in 0.2% chlorhexidine around implant, into defect and under the mucoperiosteal flap. Leave *in situ* for 5 minutes.
6. Remove gauze and wash defect with tetracycline solution 1 gm in 20 ml of sterile saline.
7. Graft defect with hydroxyapatite bone mineral of allogeneic or xenogenic derivation rehydrated in the tetracycline solution.
8. Trim and overlay graft with double layer of resorbable collagen membrane, rehydrated in tetracycline solution.

It is usual to expect some hard and soft tissues recession postoperatively, which may result in exposure of implant surface and as such place the implants to future risk of periimplant mucositis. However, this also has the advantage that it results in pocket reduction thereby reducing the risk of an infective periimplantitis. As such, regular follow-up and occasional decontamination therapy as described for the treatment of mucositis is recommended.

IMPLANT MAINTENANCE

Cumulative Interceptive Supportive Therapy

- The principle of this method is to detect periimplant infections as early as possible and to intercept the problems with appropriate therapy.
- The basis for this system is a regular recall of the implant patient and the repeated assessment of the following key parameters around each implant.
 - The presence of plaque
 - The bleeding tendency of the periimplant tissues
 - Suppuration
 - Presence of periimplant pockets
 - Radiological evidence of bone loss.
- Optimally, an implant should yield negative results for all these parameters. In this case, no therapy is needed and one may consider increasing the length of recall interval.
- If plaque and/or an increased tendency to bleed are detected, then the implants are mechanically cleaned using a rubber cup and polishing paste. Instruments made of softer material than titanium may be used to remove hard deposits.
 - Oral hygiene practices should be checked and the proper plaque control technique should be instructed and reinforced.
 - In the presence of pus or if first signs of periimplant tissue destruction are detected (pockets 4-5 mm and slight bone loss), the periimplant pockets are irrigated with 0.2% chlorhexidine and the patient is advised to rinse twice daily with 0.12% chlorhexidine (A) along with local application of antiseptic (B).
 - If pocket depth >5 mm, radiograph is taken. If there is clear evidence of bone loss, then a microbiological sample is taken. Evidence of anaerobic flora, treatment A+B and in addition systemic antimicrobial therapy (C)
 - If the bone destruction has advanced considerably, surgical intervention to correct the tissue morphology on to apply GBR techniques may be necessary (D).
 - The goal of this cumulative treatment approach is to intercept periimplant tissue destruction as early as possible.

Removal of Failed Implants

Indications for removal are as follows:

- Severe periimplant bone loss (>50% of implant length)
- Bone loss involving implant vents or hole
- Unfavorable advanced bone defect (one wall)
- Rapid, severe bone destruction (with in 1 year of loading)

- Nonsurgical or surgical therapy ineffective
- Esthetic area precluding implant surface exposure
- Demonstrates mobility.

After the implants are removed, the ridge defects can be reconstructed to their original level using bone graft and membrane techniques. This treatment enables the clinician to place new implants in a previously compromised situation.

SUMMARY

Periimplant lesions may develop after several years. Patients who have lost their teeth due to periodontal disease seem to be at greater risk. Although several antiinfective treatment strategies have demonstrated beneficial clinical effects in humans (ex, resolution of inflammation, decrease in probing depth and gain of bone in the defects), there is insufficient evidence to support a specific treatment protocol. Available studies on the treatment of periimplantitis have included only a small number of subjects, and in general, the study periods have been relatively short. To date, there is no reliable evidence that suggests which interventions could be the most effective for treating periimplantitis. This is not to say, however, that currently used interventions are not effective.

REFERENCES

1. Dahlin C, Nikfarid H, Alsén B, Kashani H. Apical periimplantitis: Possible predisposing factors, case reports and surgical treatment suggestions. *Clin Implant Dent Relat Res* 2009;11(3):222-27.
2. Albrektsson T, Isidor F. Concensus report of session IV. In: Lang NP, Karring T (Eds). *Proceedings of the 1st european workshop on periodontology*. London: Quintessence Publishing 1994:365-69.
3. Emrani J, Chee W, Slots J. Bacterial colonization of oral implants from nondental sources. *Clin Implant Dent Relat Res* 2009;11(2):106-12.
4. Sammons RL, Lumbikanonda N, Gross M, Cantzler P. Comparison of osteoblast spreading on microstructured dental implant surfaces and cell behavior in an explant model of osseointegration. A scanning electron microscopy study. *Clin Oral Implant Res* 2005;16:657-66.
5. Myshin HL, Wiens JP. Factors affecting soft tissue around dental implants: A review of the literature. *J Prosthet Dent* 2005;94:440-44.
6. Newman MG, Flemming TF. Periodontal considerations of implants and implant associated microbiota. *J Dent Educ* 1988;52:737-44.
7. Roos-Jansåker A-M, Lindahl C, Renvert H, Renvert S. Nine- to fourteen-year follow-up of implant treatment. Part II: presence of peri-implant lesions. *J Clin Periodontol* 2006;33:290-95.
8. Klinge B, Hultin M, Berglundh T. Peri-implantitis. *Dent Clin North Am* 2005;49:661-76.
9. Rosenberg ES, Cho SC, Elian N, Jalbout ZN, Froum S, Evian CI. A comparison of characteristics of implant failure and survival in periodontally compromised and periodontally healthy patients: A clinical report. *Int J Oral Maxillofac Implants* 2004;19:873-79.
10. van Steenberghe D, Naert I, Jacobs R, Quirynen M. Influence of inflammatory reactions vs occlusal loading on periimplant marginal bone level. *Adv Dent Res* 1999;13:130-35.
11. Mombelli A. Microbiology and antimicrobial therapy of periimplantitis. *Periodontol* 2000 2002;28:177-89.
12. Mombelli A. Etiology, diagnosis and treatment considerations in peri-implantitis. *Curr Opin Periodontol* 1997;4:127-36.
13. Mombelli A, Lang NP. The diagnosis and treatment of periimplantitis. *Periodontol* 2000 1998;17:63-76.
14. Lang NP, Wilson TG, Corbet EF. Biological complications with dental implants: Their prevention diagnosis and treatment. *Clin Oral Implant Res* 2000;11:146-55.
15. Listgarten MA, Lai CH. Comparative microbial characteristics of failing implants and periodontally diseased teeth. *J Periodontol* 1999;70:431-37.
16. Sorsa T, Tervahartala T, Stenman M, Suomalainen K, Mantyla P. Chair-side diagnostic point-of-care MMP-tools in periodontitis and peri-implantitis. *Nordic Dentistry Yearbook 2004b*, Quintessence Publishing Co Ltd, Lyngby, Denmark 79-95.
17. Bower RC, Radny NR, Wall CD, Henry PJ. Clinical and microscopic findings in edentulous patients 3 years after incorporation of osseointegrated implant-supported bridge work. *J Clin Periodontol* 1989;16:580-87.
18. Lekholm U, Ericsson I, Adell R, Slots J. The condition of the soft tissues at tooth and fixture abutments supporting fixed bridges. A microbiological and histological study. *J Clin Periodontol* 1986;13:558-62.
19. Ong ES, Newman HN, Wilson M, Bulman JS. The occurrence of periodontitis-related microorganisms in relation to titanium implants. *J Periodontol* 1992;63:200-05.
20. Alcoforado GA, Slots J. *Actinobacillus actinomycetemcomitans* and black-pigmented bacteroides in advanced periodontitis in man. Theoretical and practical considerations. *Rev Port Estomatol Cir Maxilofac* 1990;31:89-94.
21. Alcoforado GA, Rams TE, Feik D, Slots J. Microbial aspects of failing osseointegrated dental implants in humans. *J Parodontol* 1991;10:11-18.
22. Xu L, Yu Z, Lee HM, Wolff MS, Golub LM, Sorsa T, Kuula H. Characteristics of collagenase-2 from gingival crevicular fluid and peri-implant sulcular fluid in periodontitis and periimplantitis patients: Pilot study. *Acta Odontol Scand* 2008;66:219-24.
23. Norton MR. Marginal bone levels at single-tooth implants with a conical fixture design. The influence of surface macro- and microstructure. *Clin Oral Impl Res* 1998;9:91-99.
24. Kalykakis GK, Mojon P, Nisengard R, Spiekermann H, Zafiropoulis G-G. Clinical and microbial findings on osseointegrated implants: Comparisons between partially dentate and edentulous subjects. *Eur J Prosthodontics and Rest Dent* 1998;6:155-59.
25. Karoussis I, Müller S, Salvi G, Heitz-Mayfield L, Brägger U, Lang N. Association between periodontal and peri-implant conditions—a 10-year prospective study. *Clin Oral Impl Res* 2004;15:1-7.

26. Romanos G, Nentwig G. Regenerative therapy of deep peri-implant infrabony defects after CO₂ laser implant surface decontamination. *Int J Periodont and Rest Dent* 2008;28: 245-55.
27. Norton MR. Multiple single-tooth implant restorations in the posterior jaws: Maintenance of marginal bone levels with reference to the implant-abutment microgap. *Int J Oral and Maxillofac Implants* 2006;21:777-84.
28. Deppe H, Greim H, Brill T, Wagenpfeil S. Titanium deposition after peri-implant care with carbon dioxide laser. *Int J Oral and Maxillofac Implants* 2002;17:707-14.
29. Bach G, Neckel C, Mall C, Krekeler G. Conventional versus laser-assisted therapy of peri-implantitis – A 5-year comparative study. *Implant Dent* 2000;9:236-46.
30. Mombelli A, Feloutzis A, Brägger U, Lang N. Treatment of peri-implantitis by local delivery of tetracycline: Clinical, microbiological and radiological results. *Clin Oral Impl Res* 2001;12:287-94.

ABOUT THE AUTHORS

Himanshu Khashu (Corresponding Author)

Professor, Department of Periodontics, Sudha Rustagi College of Dental Sciences and Research, Faridabad, Haryana, India
Phone: +91-9818339669, e-mail: adhiman10@yahoo.co.in

CS Baiju

Professor and Head, Department of Periodontics, Sudha Rustagi College of Dental Sciences and Research, Faridabad, Haryana, India

Gunjan Gupta

Postgraduate Student, Department of Periodontics, Sudha Rustagi College of Dental Sciences and Research, Faridabad, Haryana, India

Praful Bali

Prosthodontist and Implantologist, Private Practitioner, New Delhi, India