

A Simplified Approach for Achieving Harmonious Occlusion in Implant Supported Complete Arch Fixed Prosthesis

¹Suresh S, ²Nandakishore B

¹Professor and Head, Department of Prosthodontics, Darshan Dental College and Hospital, Udaipur, Rajasthan, India

²Senior Lecturer, Department of Prosthodontics, Darshan Dental College and Hospital, Udaipur, Rajasthan, India

Correspondence: Suresh S, Professor and Head, Department of Prosthodontics, Darshan Dental College and Hospital, 202 Ahinsa Apartment, New Hansa Puri, Fatehpura, Udaipur-313001, Rajasthan, India, Phone: 9829573481, Fax: 0294-2452273 e-mail: drsuresh72@gmail.com

ABSTRACT

Occlusal philosophy for dental implants in complete arch prosthesis depends on several parameters. The occlusal philosophy selected should also satisfy patient's esthetic and functional demands of patient. This case report is demonstration of simplified approach in establishing harmonious occlusion at centric and eccentric mandible positions. Establishing guidance by provisional restoration ensured predictable occlusion in final restoration and also minimum occlusion adjustment at final insertion stage.

Keyword: Implant protected occlusion (IPO).

INTRODUCTION

The clinical success and longevity of implant supported prosthesis depends on number, position and design of implants. Designing the occlusal load to implants and underlying bone after achieving rigid fixation are important factors for long-term success of prosthesis. Main aims while developing occlusion in complete arch restoration should be to minimize overload to bone-implant interface and to develop occlusal scheme in harmony with stomatognathic system.

Occlusion is a critical factor for implant longevity because of nature of attachment of bone to titanium implant surface. If interface between implant and bone is disturbed either by sharp occlusal impact force or continuous pressure, it is unlikely that bone will regenerate and implant will be eventually lost.

Misch proposed implant-protected occlusion (IPO), which was designed to reduce occlusal force on implant prostheses. It involved several modifications of occlusal concepts, such as providing load sharing occlusal contacts, correction of load direction, increasing of implant surface areas, and elimination or reduction of occlusal contacts in implants with unfavorable biomechanics.^{1,2}

Primarily, implant occlusion encompasses several aspects like:

- Bilateral stability in centric occlusion
- Evenly distributed occlusal forces and contacts
- Minimal interferences between retruded and centric position
- Wide freedom in centric
- Anterior guidance
- Smooth, even, lateral excursive movements without any interferences.

Proper occlusal scheme decreases the magnitude of overload and reduces mechanical stresses at the crest of bone. Implant protected occlusion (IPO) concept addresses several conditions to decrease stress to implant interface, including timing of occlusal contacts, influence of implant surface area, mutually protected articulation, crown body angle to occlusal load, cusp angle of crown, cantilever distance, crown height, crown contour, protection of weakest component and occlusal material of implant crown.^{1,3} Following case demonstrates the value of preimplant prosthodontic phase⁴ and simplified approach in developing implant protected occlusion for full-arch fixed restoration.

CASE REPORT

A 50-year-old female patient presented with ailing anterior fixed prosthesis in relation to both arches and missing posterior teeth (Figs 1 and 2). Patient requested replacement of missing teeth with fixed prosthesis and esthetic enhancement (Fig. 3). A comprehensive examination was conducted inclusive of full mouth CT scan and diagnostic models mounting. CT scanning revealed bone quality (Type D3) and deficient in height in maxillary posterior regions.

Treatment Planning

As patient was not ready to undergo period of edentulousness, immediate denture was planned following removal of anterior bridge and remaining natural teeth. Once treatment planning was approved, immediate denture protocol was followed in construction and dentures were inserted following extraction of remaining natural teeth and anterior fixed partial denture.

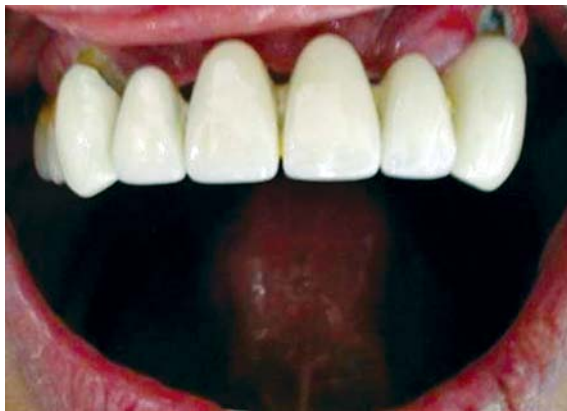

Fig. 1: Pretreatment maxilla

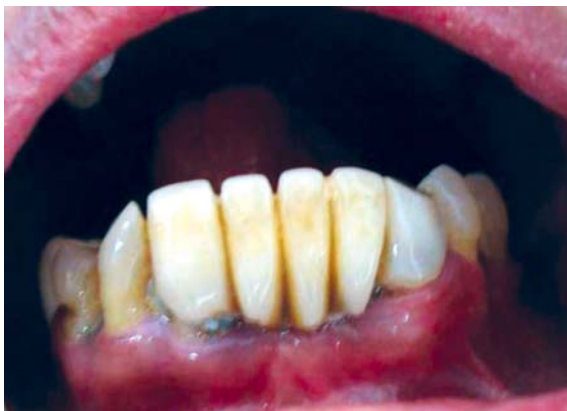

Fig. 2: Pretreatment mandible

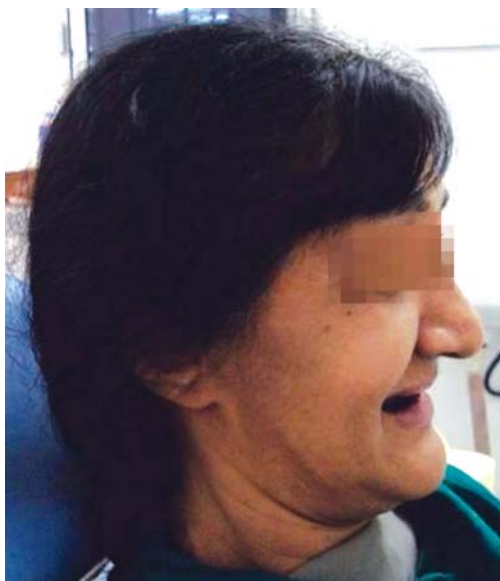


Fig. 3: Pretreatment

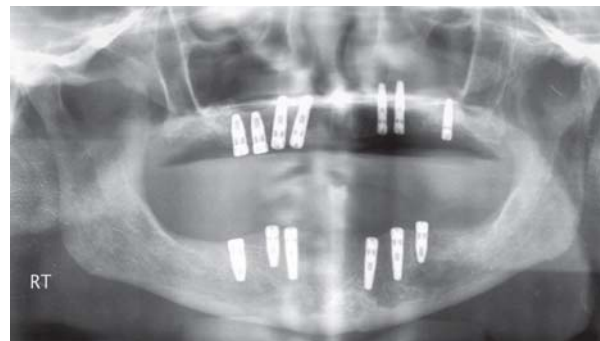


Fig. 4: Panoramic view of implants after 8 months

- ii. Soft tissue profile achieved after healing was ideal from esthetic point of view.
- iii. It provided clue about interarch space, interarch relationship, vertical dimension of occlusion, pattern of mandible movements.
- iv. Position of maxillary and mandible anterior teeth, lip line. Majority of esthetic factors in final prosthesis were decided during this phase of treatment.
- v. Duplicate of immediate dentures was used as surgical stent for implant placement.

Following healing period of 4 weeks, 8 implants were placed in maxilla after sinus lift and grafting in posterior maxilla to improve bone height and quality and 7 implants in mandible (Nobel replace) (Fig. 4). After healing period of 8 months, radiographs were made to observe bone anchorage to the fixtures and second stage surgery was carried out and healing abutments were placed. After 10 days of healing, preliminary impressions were made using hydrocolloids. Final impressions were made using stock open tray and transfer copings. Master casts were prepared using implant analogues and soft tissue replica to duplicate soft tissue contour (Fig. 5).

Temporary denture base, occlusal rims were fabricated taking care not to damage master cast. Maxillary master cast was mounted with face bow record and mandible using centric record. Try in was done to ensure centric position and occlusion. Two putty indices were prepared, one index of maxillary and mandible dentures and other esthetic index to copy position of maxillary and mandible anterior teeth position (Fig. 6).

Abutments were selected according to interarch space available and angulation of implants. Single piece metal substructure was constructed and metal try in was done to ensure passive fit and marginal fit of framework (Fig. 7). Using the putty index of dentures provisional restorations were fabricated on metal framework (Fig. 8).

Provisional restoration on metal framework served important purposes before developing final occlusion.

- i. It confirmed centric occlusion coinciding centric relation, confirmed position of master casts and according to jaw relations (Fig. 9).

Immediate Dentures

Immediate dentures played a vital role for treatment planning. Advantages of immediate dentures in this case were:

- i. It avoided period of edentulousness.

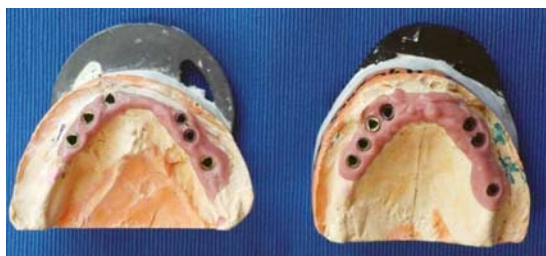

Fig. 5: Master casts

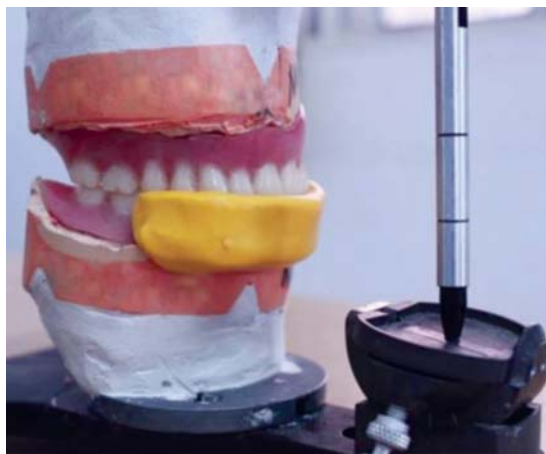


Fig. 6: Putty index to copy incisors position

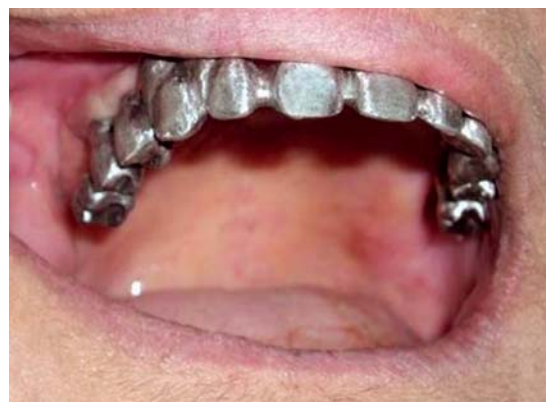

Fig. 7: Metal try in cap



Fig. 8: Provisional restoration on metal framework

- ii. Protrusive record was done on provisional restorations, which helped programming articulator for lateral condylar guidance.
- iii. Patient had opportunity to judge esthetics of final restoration.
- iv. In establishing anterior guidance (Fig. 10).

Maximum intercuspation without premature contacts at centric relation was beginning point of developing final occlusion. Mutually protected occlusion scheme was followed to develop occlusal scheme. A mutually protected occlusion occurs where posterior teeth protect the anterior teeth in centric position. The centric stops on the posterior teeth also help to prevent excess loading transferred to temporomandibular joint.^{5,6}

Hobo's following guidelines were followed while designing occlusion in final prosthesis:⁵

1. Occlusal anatomy designed to direct occlusal forces along long axis of the fixtures.
2. Point contacts were designed rather than area contacts.
3. Functional sluiceways were made for food flow and to create pathways for opposing cusps.
4. Buccolingual width was kept minimum.
5. Occlusal adjustments were done in centric relation followed by eccentric positions using occlusal strips.
6. Minimal occlusal contacts at cantilever region.

At delivery of final restoration, final occlusal adjustments were done in two stages. In first stage before final cementation, prosthesis were fastened on abutments, patient mandible was guided to centric relation and asked to close until first contact was made. At this movement, direction of mandible shift to centric closure from the first contact was noted. After locating premature contact, marked with occlusal paper, it is adjusted using white stone. After correcting centric premature contacts, prematurities at eccentric mandible position were corrected (Fig. 15). Patient was instructed to make right and left lateral movement, make light contact, then close completely into maximum

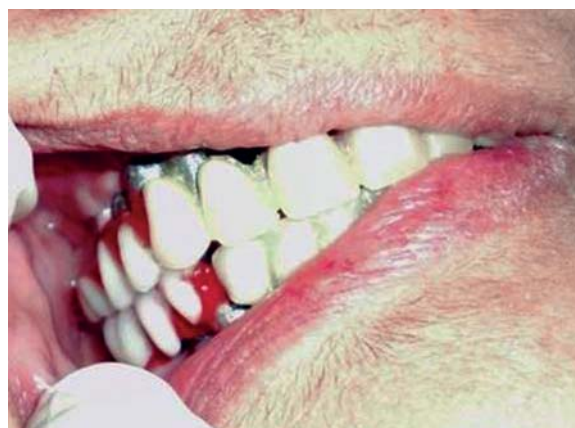

Fig. 9: Confirmation of centric recording using provisional restoration

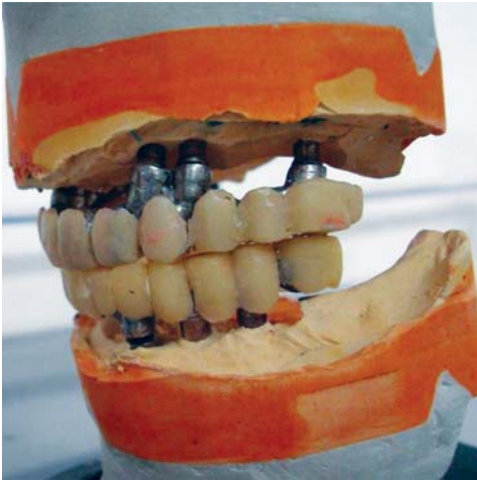


Fig. 10: Provisional restoration

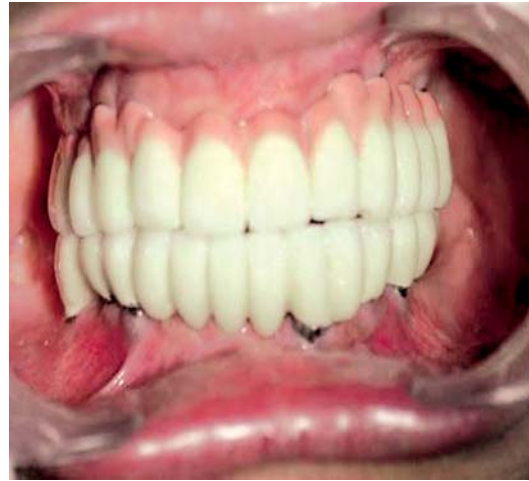

Fig. 14: Frontal view of prosthesis showing maximum intercuspation

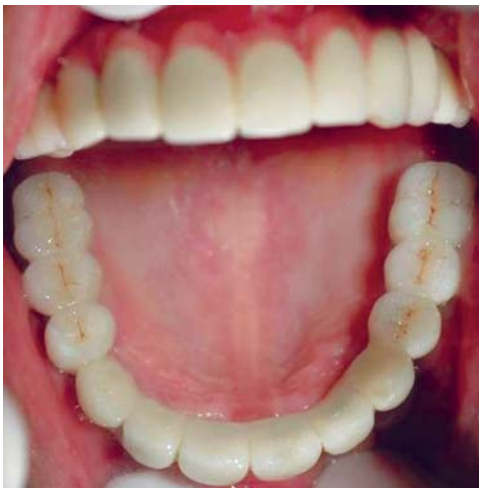

Fig. 11: Maxillary restoration *in situ*

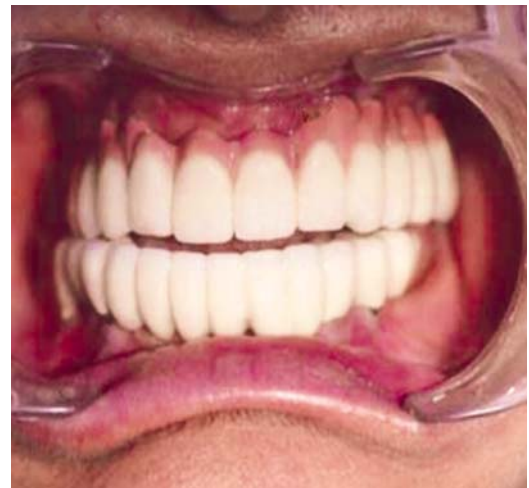

Fig. 15: Lateral movement showing no interferences

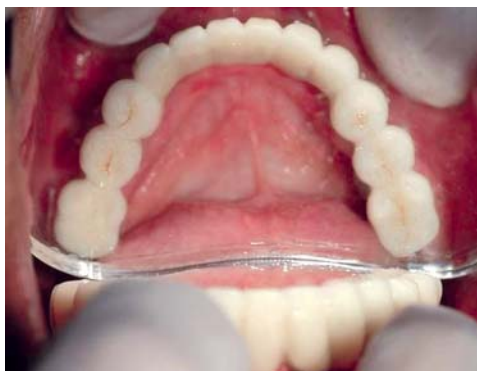

Fig. 12: Mandible restoration *in situ*

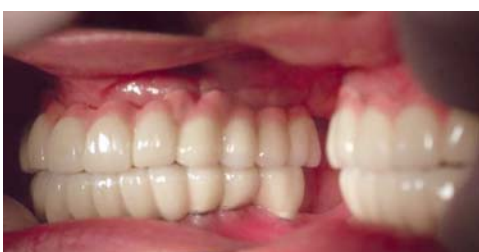

Fig. 13: Left lateral view of prosthesis

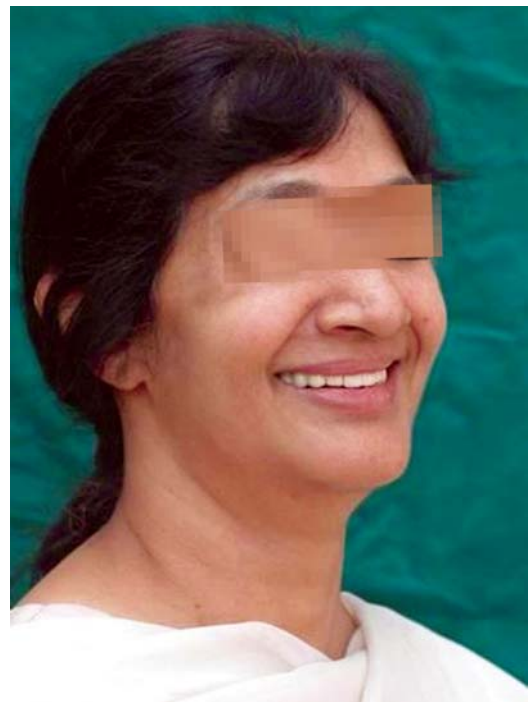

Fig. 16: Post-treatment

intercuspatation and interferences were adjusted. Finally interferences in protrusive movement when teeth were brought edge-to-edge relation were adjusted. Prosthesis was luted using temporary luting agent for one week. At second stage, further occlusal corrections were done after evaluating patient's perception and soft tissue status around abutments. Finally prosthesis was cemented using zinc phosphate and patient was educated about oral hygiene care and follow-up appointments (Figs 11 to 14).

An integral part of IPO is regular evaluation and control of occlusal contact at scheduled hygiene appointments. This permits correction of minor variations occurring during long-term function. It also helps to prevent porcelain fracture and other stress related complications. Above philosophy was employed to ensure long-term prognosis of prosthesis.¹

Above case demonstrates a vital role of removable prosthesis in developing occlusion before the placement of implants to achieve predictable success in occlusion of final prosthesis. The confirmation of occlusion and esthetic factor

by provisional restoration at metal try in stage avoided occlusal errors in final restoration. Two stage occlusal correction at final insertion phase provided opportunity to further refine and achieve harmonious occlusion (Fig. 16).

REFERENCES

1. Misch Carl E. Elsevier Mosby. Dental implant prosthetics.
2. Weinberg Lawrence A. Atlas of tooth supported and Implant supported prosthodontics; Chapter 5, 67-84; Quintessence publishing Co.
3. Lee Dong-Hwan. Myths and misbelief of biomechanics and occlusion in implant therapy. Uploads lecture on implant occlusion. Accessed October 2009.
4. Misch Carl E. Elsevier Mosby: Contemporary implant dentistry (2nd ed); Chapter 10, 135-39.
5. Hobo Sumiyo, Takayama Hisao. Oral rehabilitation clinical determinants of occlusion: Occlusion for osseointegrated implants Quintessence publishing Co Chapter 11, 119-34.
6. Hobo Sumiya, Ichida Eji, Garcia Lily T. Osseointegration and Occlusal Rehabilitation; Quintessence Publishing Company Chapter 18, 315-28.