

CASE REPORT

Vascularized Interpositional Periosteal Connective Tissue Flap Technique to correct Soft Tissue Defect around Maxillary Anterior Implant

¹Chitra Agarwal, ²AB Tarun Kumar, ³MG Triveni, ⁴Dhoom Singh Mehta

ABSTRACT

The esthetic outcome of implant-supported restorations has become increasingly important, especially for single-tooth implants in the esthetic zone. Because of the morphologic alterations that occur following tooth extraction, augmentation procedures are often necessary before, during, or after implantation to achieve an esthetically pleasing result. There are many periodontal plastic surgery procedures available to esthetically reconstruct deficiencies in both hard and soft tissues; however each technique has its own limitation. A newer technique, vascularized interpositional periosteal connective tissue flap has been introduced as an alternative to these techniques which allows the clinician to perform large volume soft tissue augmentation in esthetic sites with a single procedure. In the present case report, long-term result of soft tissue augmentation with VIP-CT flap is presented where in peri-implant recession was noted as a complication.

Keywords: VIP-CT flap, Soft tissue augmentation, Esthetic.

How to cite this article: Agarwal C, Kumar ABT, Triveni MG, Mehta DS. Vascularized Interpositional Periosteal Connective Tissue Flap Technique to correct Soft Tissue Defect around Maxillary Anterior Implant. *Int J Oral Implantol Clin Res* 2014;5(1):24-28.

Source of support: Nil

Conflict of interest: None

INTRODUCTION

Alveolar ridge defects results in unesthetic restoration of an implant support or fixed partial denture particularly in maxillary anterior region.¹ In addition, they lead to pontic or implant with phonetic and oral hygiene complications. These defects occur because of developmental defects, extraction of the teeth, bone loss due to periodontal disease or due to trauma.²

Various periodontal plastic procedures,³ have been proposed for both soft and hard tissue augmentation.⁴ These include free gingival onlay grafts, subepithelial connective tissue grafts, the palatal roll technique, hard tissue allografts or alloplasts and guided bone regeneration (GBR).⁵⁻¹⁶

Soft tissue augmentation procedures, especially with autografts, are widely accepted. They have the advantage of low cost, good predictability and can be repeated to improve the results.² Various approaches are feasible depending on the severity of the defect.^{17,18}

A newer technique, vascularized interpositional periosteal connective tissue (VIP-CT) flap has been introduced as an alternative to other techniques which allows the clinician to perform large volume soft tissue augmentation at esthetic sites with a single procedure. It has the added advantage of minimal postsurgical shrinkage, minimally invasive donor site wound, allows primary closure of donor site, maintains an intact vascular supply, provides excellent esthetic blending at the recipient site and reduced treatment time.¹⁹

In the present case report, soft tissue augmentation with VIP-CT flap was done in relation to implant displaying soft tissue recession, with the aim to meet esthetic demand in anterior maxillary region.

CASE REPORT

A healthy 28-year-old male patient reported to the Department of Periodontics, Bapuji Dental College and Hospital, Davangere, Karnataka, India on the follow-up visit after implant placement. Dental history revealed that his tooth was extracted due to trauma and an immediate implant was placed in relation to upper left front tooth. His dental record revealed that GBR had been done using combination of resorbable collagen membrane and Xenograft at the time of implant placement to correct the bone dehiscence. The patient presented with soft tissue recession creating an unesthetic smile (Figs 1 and 2). Presurgical examination showed a class III ridge defect.⁵ It was planned to do soft tissue augmentation along with guide bone regeneration but patient was unwilling to undergo bone grafting again because of the waiting period and was concerned about esthetics and prosthetic replacement of the implant.

¹Assistant Professor, ²Professor and Head, ^{3,4}Professor

¹Department of Periodontics, Jodhpur Dental College and General Hospital, Jodhpur, Rajasthan, India

²Department of Periodontics, Bapuji Implant Centre, Bapuji Dental College and Hospital, Davangere, Karnataka, India

^{3,4}Department of Periodontics, Bapuji Dental College and Hospital, Davangere, Karnataka, India

Corresponding Author: AB Tarun Kumar, Professor and Head, Department of Periodontics, Bapuji Implant Centre, Bapuji Dental College and Hospital, Davangere, Karnataka, India e-mail: tarundental@gmail.com

Keeping this in mind, the case was taken up for soft tissue augmentation by VIP-CT flap technique in relation to implant and tunnel bone grafting technique was planned as a second stage procedure. Surgical procedure was explained in detail to patient and a written informed consent was obtained.

Surgical Procedure

After obtaining adequate local anesthesia (2% lidocaine HCl with 1:100,000 epinephrine), recipient bed was prepared by giving exaggerated curvilinear-beveled incision starting at the vestibule apical to the interdental papilla of the teeth adjacent to the site and continued coronally with a slight curve as it reached the recipient site finally terminating on the palatal aspect of the ridge with abbreviated vertical releasing incisions made on the palate at the mesial and distal aspect of the recipient site. Horizontal incision was then made connecting the vertical incisions. Mucoperiosteal flap was performed to raise a buccal flap (Fig. 3). Incision at the distal aspect of the recipient site parallels the gingival margin on the oral aspect

of the adjacent tooth. Donor site preparation included the extension of this incision horizontally to the distal aspect of the 2nd premolar and following a path approximately 2 mm apical to free gingival margin of canine and premolar teeth (Fig. 4). Sharp dissection was used to create split thickness palatal flap in the premolar area similar to single incision technique. The subepithelial dissection was carried anteriorly toward the distal aspect of the canine. A vertical incision was then made at the distal aspect of sub epithelial dissection. Subepithelial connective tissue layer was elevated beginning from second premolar area toward the anterior extent of the dissection. A second incision was then initiated under tension internally at the apical extent of the previous vertical incision and extended horizontally anterior to the distal aspect of the canine. Tension releasing cutback incisions was extended into the base of the pedicle flap for flap rotation (Fig. 5).

Flap is rotated into the recipient site (Fig. 6) and rigidly immobilized with sutures placed apically (Fig. 7) and laterally (Fig. 8). Donor and recipient sites were sutured to obtain primary closure (Fig. 9) and gentle pressure was applied with moistened gauze for 10 minutes.

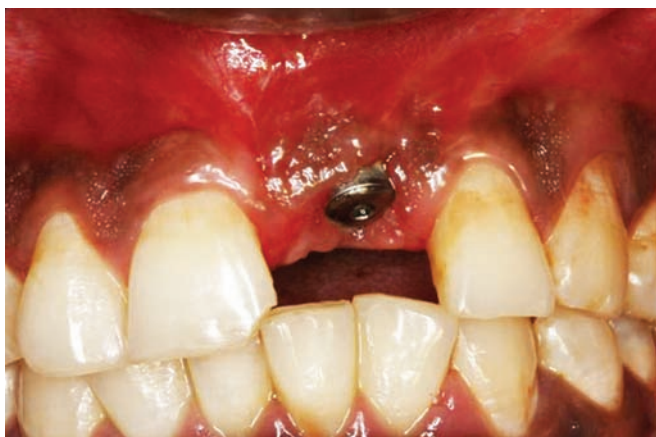

Fig. 1: Soft tissue defect

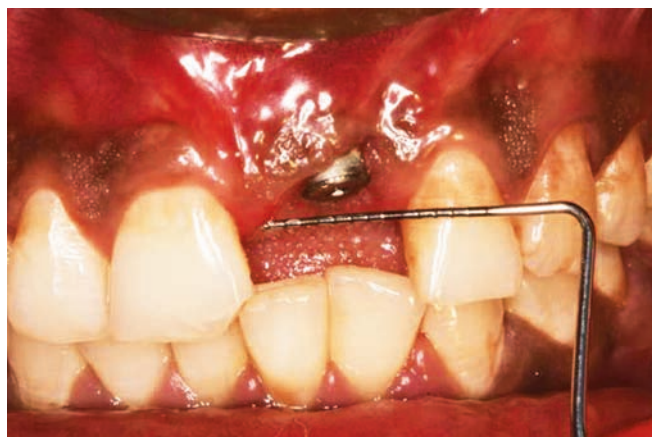


Fig. 2: Measurement showing requirement of CT pedicle

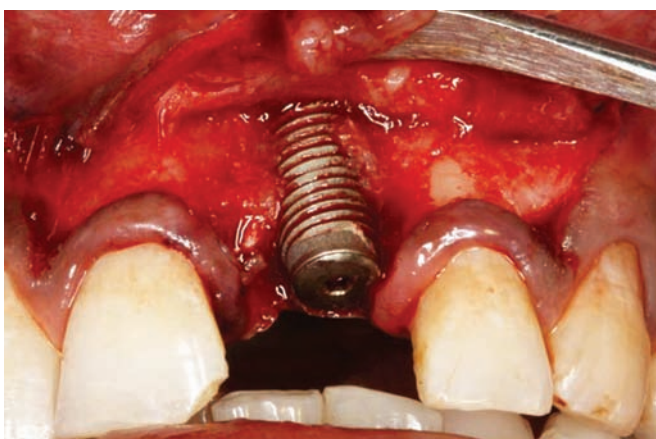


Fig. 3: Flap management with exaggerated curvilinear-beveled incision

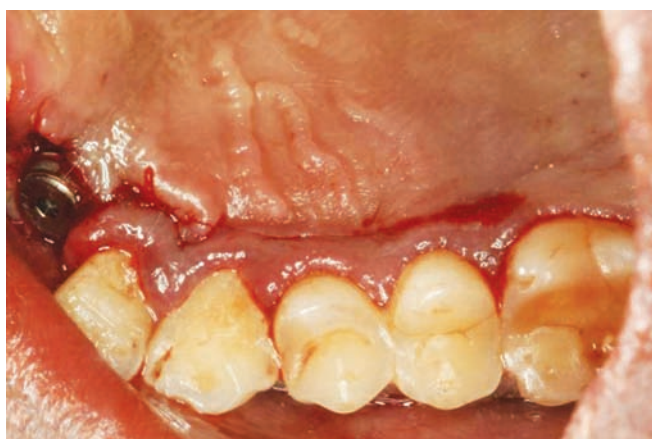

Fig. 4: Donor site incision

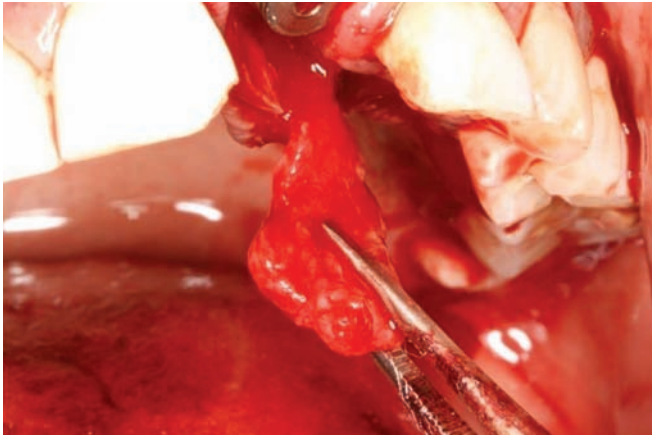


Fig. 5: Vascularized CT pedicle liberated from the palate

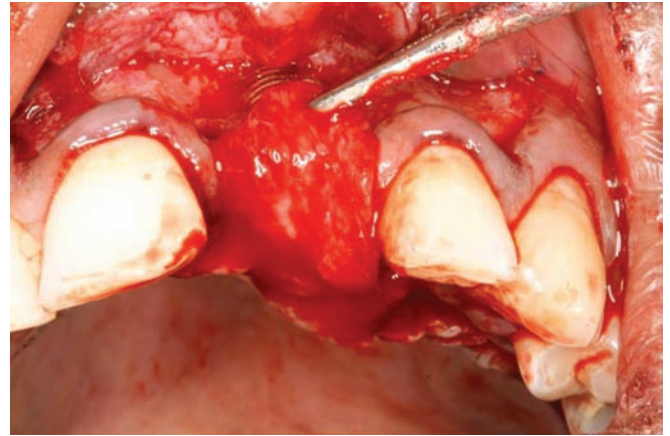


Fig. 6: CT pedicle rotated over the implant

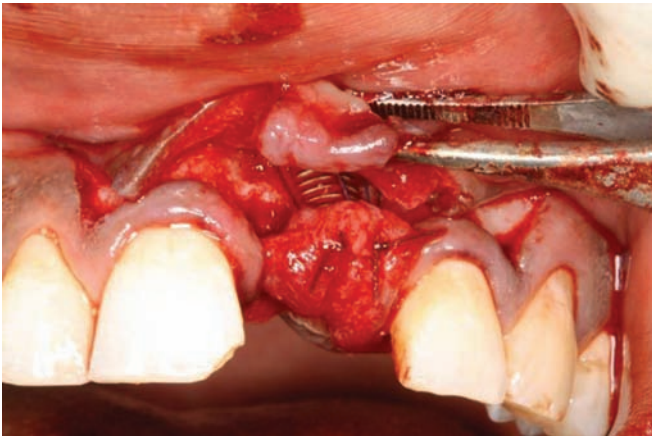


Fig. 7: VIP-CT immobilized with periosteal mattress suture

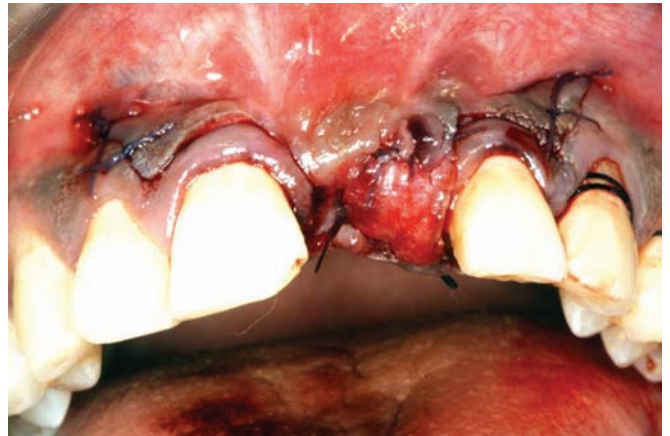

Fig. 8: Suturing of recipient site

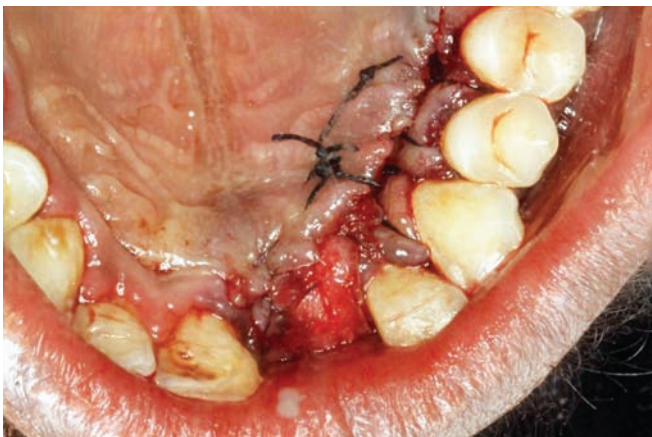

Fig. 9: Suturing of donor site

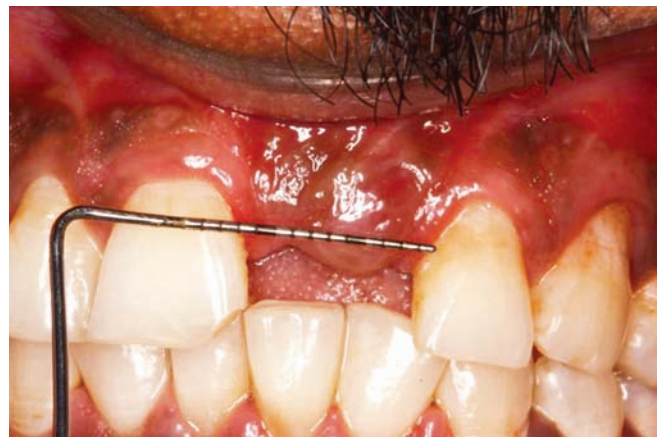

Fig. 10: One month postoperative healing

Postsurgical care included rinsing twice daily with 0.12% chlorhexidine digluconate solution during the first 2 weeks. Systemic antibiotics regimen included capsule amoxicillin 500 mg TID for 5 days and tablet ibuprofen 400 mg TID for 3 days. Sutures were removed 2 weeks after surgery. After 1 month healing, the patient was referred to department of prosthodontics for rehabilitation with fabrication of implant prosthesis.

In the present case, tremendous increase in soft tissue volume was observed one month postoperatively (Fig. 10). On

follow-up visits, there were no specific signs of inflammation or infection, complete soft tissue coverage of the implant collar was maintained and an excellent esthetic emergence and gingival contouring was observed at the most recent visit, i.e. 5 years after augmentation (Fig. 11). The patient showed good maintenance of oral hygiene.

DISCUSSION

Vascularized interpositional periosteal connective tissue flap technique seems to be good substitute of others tech-

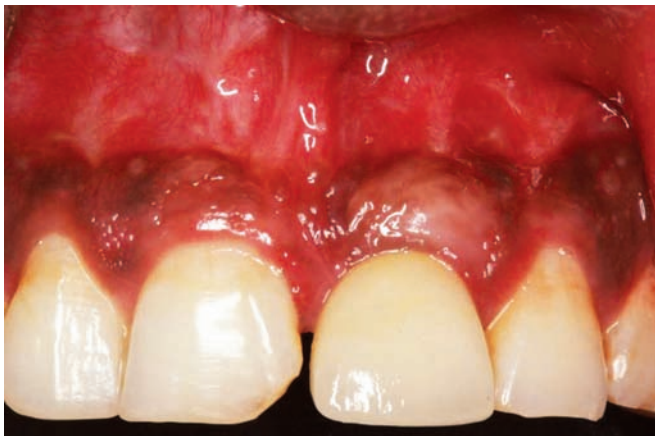

Fig. 11: Five-year follow-up

nique for large volume soft tissue augmentation at esthetic sites with a single procedure.

There are many periodontal plastic surgical procedures available to correct ridge defects in both hard and soft tissues; however each technique has its own scope limitation. Free soft tissue grafts require two surgical sites and their survival depends completely on blood supply of recipient bed resulting in increased chances of necrosis. Poor color match is associated with free autograft.⁵ Subepithelial connective tissue graft⁹ often requires several procedures to reconstruct large volume soft tissue defects.²⁰⁻²²

However, the VIP-CT flap technique involves the tension-free closure of the cover flaps. The random pattern of this periosteal connective tissue flap from within the palatal soft tissue allows the rotation of the flap to the recipient site and interpositioned beneath the flap. The flap is flexible enough to allow augmentation of soft tissue between ipsilateral premolars and central incisors. Periosteal connective tissue flap is supplied by vascular plexus which receives branches from greater palatine artery as it approaches the incisive foramen. As in subepithelial connective tissue graft, the size and shape of the palate may limit the use of this technique.²⁰⁻²²

Although the site revealed both soft tissue and hard tissue defect, patient was not willing to undergo hard tissue augmentation at that particular time. His prime concern was to achieve esthetics and prosthesis immediately because of personal reasons. Therefore we chose the technique which could result in large soft tissue volume augmentation. In the follow-up visit, tunneling bone grafting technique was planned but the patient did not turn up for the procedure. Patient reported back 3 years after the soft tissue augmentation and restoration which revealed complete resolution of peri-implant soft tissue defect. Patient was satisfied with the existing situation as the implant was immobile and esthetically pleasing.

The peri-implant health and esthetics depends primarily on presence of adequate marginal gingival thickness and

sufficient width of keratinized tissue at an early phase of the implant uncover-surgery. The biotypes of the peri-implant mucosa^{23,24} determine the degree of mucosal collapse. Free gingival graft or subepithelial connective tissue graft results in soft tissue augmentation. However, these do not enhance the thickness of the marginal gingiva. Unlike a free subepithelial connective tissue graft, a pedunculated connective tissue design not only augments the ridge deficiency with better vascular supply but also thickens the marginal gingiva around an uncovered implant.²⁵

Vascularized interpositional periosteal connective tissue flap when used for simultaneous hard and soft tissue augmentation in the anterior region; a slight gingival configuration changes had been observed for a period of 6 years, similar tissue response and favorable esthetic results were appreciated by patients and clinician.²⁶

The amount of horizontal and vertical soft tissue augmentation obtained is consistently superior to that obtained with the free soft tissue grafting techniques. This technique has also proven useful in the treatment of compromised sites where existing soft tissue biotypes is not good and severely scarred rendering them inadequate to support required hard tissue site development. Vascularized interpositional periosteal connective tissue flap maintain intact circulation and showed decreased post surgical contraction. It has also shown predictable means of submerging implant in anterior area when an unexpected soft tissue dehiscence compromises the final esthetic result.

CONCLUSION

The present case report showed that the VIP-CT flap technique can provide predictable soft tissue augmentation in the esthetic area. A controlled study with additional cases will be required to prove the predictability of the procedure described in the present case report.

REFERENCES

1. Yeung SCH. Biological basis for soft tissue management in implant dentistry. *Aust Dent J* 2008;53:(1 Suppl):S39-S42.
2. Gasparini DO. Double-fold connective tissue pedicle graft: a novel approach for ridge augmentation. *Int J Periodontics Restorative Dent* 2004;24:280-287.
3. Miller PD Jr. Periodontal plastic surgery. *Curr Opin Periodontol* 1993;136-143.
4. Seibert JS, Salama H. Alveolar ridge preservation and reconstruction. *Periodontol* 2000;1996;11:69-84.
5. Seibert JS. Reconstruction of deformed, partially edentulous ridges, using full thickness onlay grafts. Part I. Technique and wound healing. *Compend Contin Educ Dent* 1983;4:437-453.
6. Seibert JS. Reconstruction of deformed, partially edentulous ridges, using full thickness onlay grafts. Part II. Prosthetic/periodontal interrelationships. *Compend Contin Educ Dent* 1983; 4:549-562.

7. Abrams L. Augmentation of the deformed residual edentulous ridge for fixed prosthesis. *Compend Contin Educ Dent* 1980; 1:205-213.
8. Garber DA, Rosenberg ES. The edentulous ridge in fixed prosthodontics. *Compend Contin Educ Dent* 1981;2:212-223.
9. Langer B, Calagna L. The subepithelial connective tissue graft. A new approach to the enhancement of anterior cosmetics. *Int J Periodontics Restorative Dent* 1982;2:22-33.
10. Allen EP, Gainza CS, Farthing GG, Newbold DA. Improved technique for localized ridge augmentation. A report of 21 cases. *J Periodontol* 1985;56:195-199.
11. Remagen W, Prezmecky L. Bone augmentation with hydroxyapatite: histological findings in 55 cases. *Implant Dent* 1995; 4:182-188.
12. Buser D, Dula K, Belser UC, Hirt HP, Berthold H. Localized ridge augmentation using guided bone regeneration. II. Surgical procedure in the mandible. *Int J Periodontics Restorative Dent* 1995;15:10-29.
13. Buser D, Ruskin J, Higginbottom F, Hardwick R, Dahlin C, Schenk RK. Osseointegration of titanium implants in bone regenerated in membrane-protected defects: a histologic study in the canine mandible. *Int J Oral Maxillofac Implants* 1995; 10:666-681.
14. Smukler H, Barboza EP, Burliss C. A new approach to regeneration of surgically reduced alveolar ridges in dogs: a clinical and histologic study. *Int J Oral Maxillofac Implants* 1995 Sep-Oct;10(5):537-551.
15. Doblin JM, Salkin LM, Mellado JR, Freedman AL, Stein MD. A histologic evaluation of localized ridge augmentation utilizing DFDBA in combination with e-PTFE membranes and stainless steel bone pins in humans. *Int J Periodontics Restorative Dent* 1996;16:120-129.
16. Fowler EB, Breault LG. Ridge augmentation with a folded acellular dermal matrix allograft: a case report. *J Contemp Dent Pract* 2001;3:31-40.
17. Hürzeler MB, Mohrenschildt SV, Zuhr O. Stage-two implant surgery in the esthetic zone: a new technique. *Int J Periodontics Restorative Dent* 2010;30:187-193.
18. Pini Prato GP, Cair F, Tinti C, Cortellini P, Muzzi L, Mancini EA. Soft tissue reconstruction is useful in the treatment of ridge deformities, especially in cases of mild or moderate ridge defects. *Int J Periodontics Restorative Dent* 2004;24:434-445.
19. Sclar A. Vascularized interpositional periosteal-connective tissue (VIP-CT) Flap. In: Sclar A, editor. *Soft tissue and esthetic considerations in implant dentistry*. Chicago, Quintessence Publishing, 2003. p. 163.
20. Studer S, Naef R, Schärer P. Adjustment of localized alveolar ridge defects by soft tissue transplantation to improve mucogingival esthetics: a proposal for clinical classification and an evaluation of procedures. *Quintessence Int* 1997;28:785-805.
21. Seibert J, Lindhe J. Esthetics in periodontal therapy. In: Lindhe J, Karring T, Lang N, editors. *Clinical Periodontology and Implant Dentistry*. 3rd ed. Copenhagen: Munksgaard, 1997:647-681.
22. Scharf D, Tarnow D. Modified roll technique for localized alveolar ridge augmentation. *Int J Periodontics Restorative Dent* 1992;12:415-425.
23. Kan JY, Rungcharassaeng K, Umezumi K, Kois JC. Dimensions of peri-implant mucosa: an evaluation of maxillary anterior single implants in humans. *J Periodontol* 2003;74:557-562.
24. Spear FM. Maintenance of the interdental papilla following anterior tooth removal. *Pract Periodontics Aesthet Dent* 1999; 11:21-28.
25. Park SH, Wang HL. Pouch roll technique for implant soft tissue augmentation: a variation of the modified roll technique. *Int J Periodontics Restorative Dent* 2012;32:e116-e121.
26. Kim CS. Long-term results from soft and hard tissue augmentation by a modified vascularized interpositional periosteal-connective tissue technique in the maxillary anterior region. *J Oral and Maxillofac Surg* 2012;70:484-491.