

# Piezosurgical Mandibular Ridge Expansion for Immediate Implant Placement

Nettemu Sunil Kumar, Nettem Sowmya

## ABSTRACT

Edentulism of a long standing nature leading to severe alveolar ridge atrophy with a resultant thin ridge often pose a great challenge to the clinicians for rendering implant supported prosthesis in that region. The ideal treatment in such a scenario will be the ridge expansion procedure for achieving an increase in the available bone volume at the implantation site. The space thus created between the bony walls renders an ideal regenerative and implant-integrating condition. The use of a piezosurgical device for performing a piezoelectric alveolar ridge expansion procedure permits a precise and tactile controlled osteotomy facilitating implant placement in anatomic situations previously impossible in a single stage surgical procedure. This case report demonstrates the ease of mandibular ridge splitting with the use of piezosurgical principle facilitating immediate implant placement in a severely resorbed thin edentulous alveolar ridge.

**Keywords:** Piezosurgery, Ridge splitting, Immediate implant placement.

**How to cite this article:** Kumar NS, Sowmya N. Piezosurgical Mandibular Ridge Expansion for Immediate Implant Placement. *Int J Oral Implantol Clin Res* 2012;3(1):47-50.

**Source of support:** Nil

**Conflict of interest:** None declared

## INTRODUCTION

Optimal positioning of dental implant plays a vital role in the successful osseointegration at the implanted site. And, osseointegrated implants are only as successful as the final restorations they ultimately support. This focus on 'restoration-driven implant placement' is synonymous with the goal of positioning the implant not necessarily where the most bone is but in the position ideal for prosthetic finalization and enhancement of function.<sup>1-5</sup>

The presence of a thin edentulous ridge often presents a clinical challenge for proper positioning of endosseous dental implants. Also, when bone atrophy is more severe because of edentulism of a long standing nature and the residual ridge is less than 3 mm, the remaining bone is often highly mineralized and characterized by the presence of cortical bony walls separated by a thin cancellous bone marrow layer. The ideal treatment in such situations will be the ridge splitting procedure that does not remove bone from the implant site but dislocates it, increasing the volume of available bone at the implantation site. The resulting space between the bony walls creates ideal regenerative and

implant-integrating conditions. This technique is also characterized by a valid vascular supply and a rich osteoinductive cellularity, which comes from the diversion of the medulla.<sup>6</sup> Finally, the morbidity associated with the use of a second surgical site for harvesting autogenous bone transplants<sup>7-14</sup> or micromovements of implants formed by a particulate graft environment is avoided.<sup>15</sup>

The piezosurgery device invented by Dr Tomaso Vercellotti, uses a modulated functional working frequency of 25-30 kHz at which only the alveolar bone can be cut. The piezoelectric alveolar ridge expansion procedure permits a precise and tactile controlled osteotomy facilitating implant placement in anatomic situations previously impossible in a single stage surgical procedure.

This case report describes the use of a piezoelectric device for mandibular ridge splitting thereby creating an ideal milieu for immediate implants placement.

## CASE REPORT

A 55-year-old female patient presented to the department of periodontology and oral implantology with a chief complaint of missing lower right back teeth and consequent inability in chewing food using that side of the mouth. On eliciting the dental history, the patient revealed that she had undergone extractions of multiple posterior teeth due to dental caries 20 years back and replacement with fixed prostheses was done in relation to upper right and left posterior teeth as well as lower left posterior region. There was no replacement done in relation to lower right posterior region. Patient had also undergone restorations of multiple cervical abrasions on the anterior teeth. Patient was unwilling for removal and replacement of the maxillary fixed prostheses and requested treatment confined to the mandibular arch. Patient gave weightage to functional restoration of the dentition over esthetics, with treatment aimed at restoring her posterior teeth to facilitate mastication in the right side. The patient reported to be a controlled diabetic and hypertensive under regular medications for the systemic conditions. The social and family history was noncontributory. Intraoral examination revealed that the fixed prosthesis in the upper posterior right region was placed over supraerupted first premolar and second molar. The occlusal plane and interarch vertical dimensions had visibly not been taken into consideration (Fig. 1).

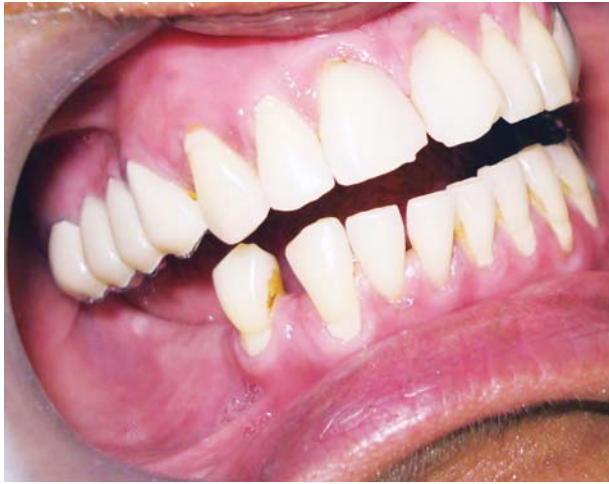

Fig. 1: Preoperative intraoral view

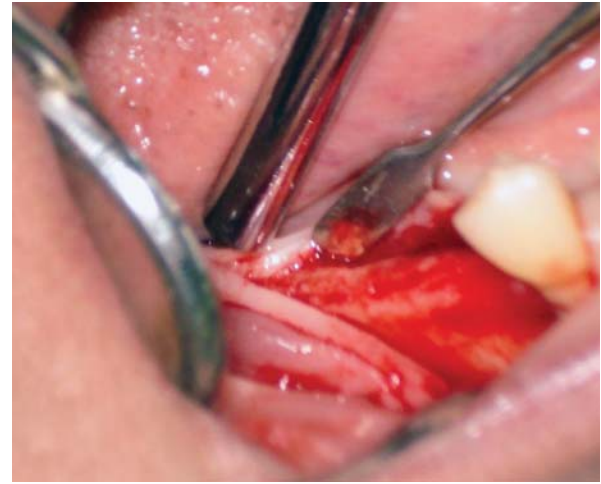


Fig. 2: Mucoperiosteal flap reflected to expose thin edentulous ridge

Bone mapping revealed a thin edentulous mandibular ridge in the right lower posterior region. Horizontal and vertical ridge augmentation was excluded from the treatment plan due to multiple factors including patient's age, systemic status, morbidity associated with a second surgical site and most importantly, the decreased interocclusal vertical dimension and spatial relationship.

A well-structured treatment plan was constructed, tailor-made to suit the patient needs involving piezosurgical mandibular ridge splitting and immediate implants placement in the lower right first molar region. An informed consent was obtained from the patient.

### Surgical Procedure

The surgical site was anesthetized by local administration of 2% lignocaine hydrochloride (LOX, Neon Laboratories Ltd, Mumbai, India) with 1:200,000 adrenaline. A conventional mucoperiosteal flap, extending from the lower right second premolar to the second molar region was reflected to obtain access and visibility to the subperiosteal surgical site (Fig. 2). Using a graduated probe, the thickness of the edentulous ridge was measured to be 2.8 to 3.0 mm.

### Piezosurgical Mandibular Ridge

#### Splitting Procedure

A sagittal osteotomy of the edentulous ridge was initiated at the center of the ridge using piezosurgical saw form tip No. 5 (Mectron, Italy) (Fig. 3) and sequential expansion of the ridge width was achieved by using piezosurgical scalpels of greater thickness and length until a mobile vestibular flap was obtained. Expansion of the ridge was achieved utilizing the elastic property of the bony plates, care taken not to fracture the bony plates. The implant drilling was initiated under copious isotonic saline irrigation. An initial

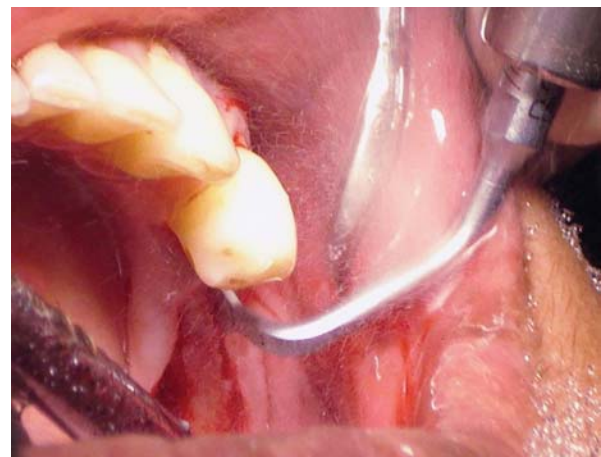
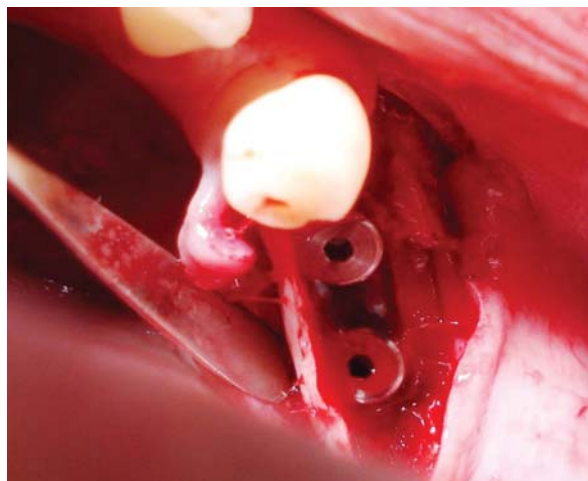


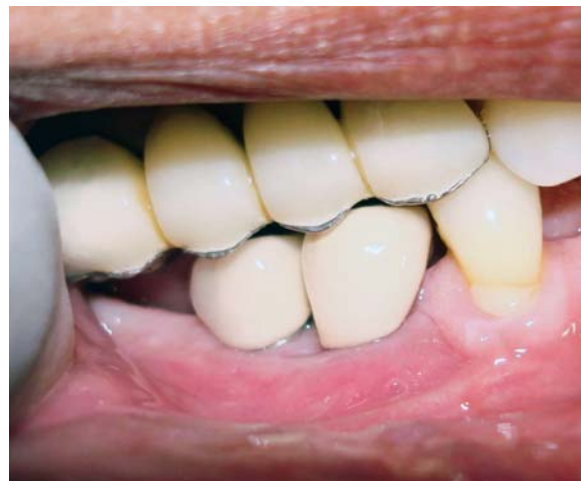Fig. 3: Piezosurgical ridge splitting

marking of the sites were performed using a round bur and subsequent osteotomies were carried out with a 2 mm drill to establish the depth and direction with the final drilling completed using a 3.65 mm drill. Two self-threaded titanium implants (3.75 mm × 10 mm) were inserted and covered with a titanium cover screw (Fig. 4). Adequate primary stability was accomplished by the residual host bone and the intact cortical walls. The space between the expanded bony plates and implants were packed precisely with bovine hydroxyapatite synthetic graft material (Bio-Oss, Geistlich Pharmaceuticals, Wolhausen, Switzerland) (Fig. 5). The tension-free flap was repositioned and sutured using an absorbable suture material (4-0 Vicryl, Ethicon, Inc., Johnson and Johnson, Somerville, NJ, USA) (Fig. 6).

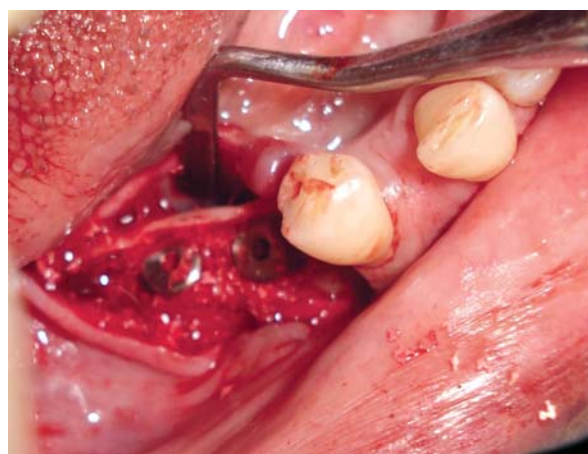
*Postoperative care:* A prescription of 10 mg Ketorolac was given in conjunction with 2 gm/day of Amoxicillin for 10 days. The patient was asked to rinse with warm saline for the first 2 weeks to promote normal flap healing without disturbing the wound. The patient was also instructed to use chlorhexidine gluconate 0.12% (Peridex, Zila Pharmaceuticals, Phoenix, AZ, USA) to facilitate plaque control.



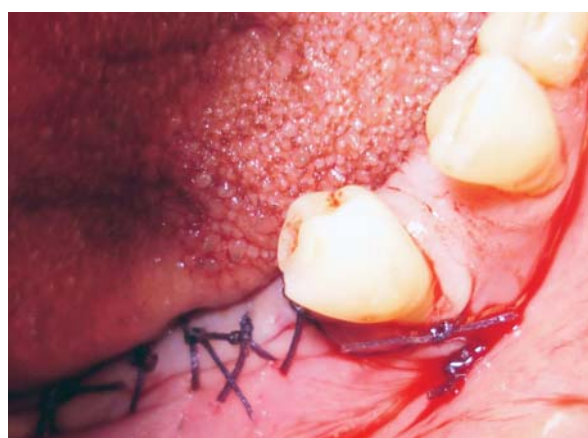**Fig. 4:** Two self-threaded implants in place



**Fig. 7:** Crown fixation done



**Fig. 5:** Bovine hydroxyapatite synthetic graft material packed in the region surrounding the implants



**Fig. 6:** Tension free flap adapted and sutured in place

There was no report of any postoperative patient discomfort or complications.

The surgical site was reviewed every 2 weeks for a period of 2 months. After 6 months of healing, the second surgery was performed to uncover the implants for abutment connection and subsequent crown placements (Fig. 7).

The patient expressed satisfaction over the treatment outcome and restoration of function.

## DISCUSSION

Numerous studies have shown that immediate placement of implants with resultant successful osseointegration can be achieved by the use of the ridge expansion technique.<sup>8,9,16,17</sup> One of the problems encountered with the mechanical separation or ridge splitting using the conventional osteotome technique is the trauma and eventual fracture of the cortical walls during separation, leading to total detachment of the vestibular cortical bone and the consequent interruption of the vascularization process, ultimately leading to bone necrosis and implant failure. The minimum thickness of the implant site for the standard method with the preparation of the implant site using burs is at least 6 mm to permit the positioning of a 3.75 mm implant and the maintenance of a buccal and palatal wall of at least 1 mm.<sup>18-21</sup> Piezosurgery has specific therapeutic advantages including a micrometric cut that limits hard tissue damage, to the bone at the structural<sup>22</sup> and a selective cut enabling the clinician to cut through hard tissues while sparing fine anatomical structures. It facilitates maintenance of a clear surgical site as a result of the cavitation effect created by irrigation and oscillation of the tip.<sup>23</sup> Also, the piezosurgical system can split a very narrow ridge with minimal loss or perforation of bone.<sup>6,24</sup> Finally, the piezosurgery can be used in dense mineralized bone because the vertical dimension of the bone is maintained while the width permits no implant insertion.

## CONCLUSION

Rehabilitation of a long standing edentulism with immediate implant placement can be performed with relative ease by the use of a piezosurgical ridge expansion technique without

the requirement for extensive augmentation procedures and avoidance of a second surgical site to augment the thin, resorbed ridge. The piezosurgical technique is a minimally invasive, safe and promising system which can be applied in all advanced and complicated cases. And, the peri-implant healing is highly predictable because it takes place in an enclosed, well protected and highly vascularized environment.

## REFERENCES

1. Garber DA, Belser UC. Restoration-driven implant placement with restoration-generated site development. *Compend Contin Educ Dent* 1995;16:796.
2. Garber DA. The esthetic dental implant: Letting restoration be the guide. *J Oral Implantol* 1996;22:45-50.
3. Sadan A, Blatz MB, Salinas TJ, et al. Single-implant restorations: A contemporary approach for achieving a predictable outcome. *J Oral Maxillofac Surg* 2004;62:73-81.
4. Zadeh HH. Implant site development: Clinical realities of today and the prospects of tissue engineering. *J Calif Dent Assoc* 2004;32:1011-20.
5. Sclar AG. Strategies for management of single-tooth extraction sites in aesthetic implant therapy. *J Oral Maxillofac Surg* 2004;62:90-105.
6. Vercellotti T. Piezoelectric surgery in implantology: A case report—a new piezoelectric ridge expansion technique. *Int J Periodontics Restorative Dent* 2000;20:359-65.
7. Simion M, Baldoni M, Zaffe D. Jawbone enlargement using immediate implant placement associated with a split-crest technique and guided tissue regeneration. *Int J Periodontics Restorative Dent* 1992;12:462-73.
8. Summers RB. A new concept in maxillary implant surgery: The osteotome technique. *Compendium* 1994;15:152.
9. Scipioni A, Bruschi GB, Calesini G. The edentulous ridge expansion technique: A five-year study. *Int J Periodontics Restorative Dent* 1994;14:451-59.
10. Engelke WG, Diederichs CG, Jacobs HG, et al. Alveolar reconstruction with splitting osteotomy and microfixation of implants. *Int J Oral Maxillofac Implants* 1997;12:310-18.
11. Bruschi GB, Scipioni A, Calesini G, et al. Localized management of sinus floor with simultaneous implant placement: A clinical report. *Int J Oral Maxillofac Implants* 1998;3:219-26.
12. Sethi A, Kaus T. Maxillary ridge expansion with simultaneous implant placement: A 5-year result of an ongoing clinical study. *Int J Oral Maxillofac Implants* 2000;5:491-99.
13. Palti A. Ridge splitting and implant techniques for the anterior maxilla [Interview]. *Dent Implantol Update* 2003;14:25-32.
14. Guirado JL, Yuguero MR, Carrion del Valle MJ, et al. A maxillary ridge-splitting technique followed by immediate placement of implants: A case report. *Implant Dent* 2005;14:14-20.
15. Strietzel FP, Nowak M, Kuchler I, et al. Peri-implant alveolar bone loss with respect to bone quality after use of the osteotome technique: Results of a retrospective study. *Clin Oral Implants Res* 2002;13:508-13.
16. Summers RB. The osteotome technique (Part 2)—the ridge expansion osteotomy (REO) procedure. *Compendium* 1994;15:422-26.
17. Summers RB. The osteotome technique (Part 3)—Less invasive methods of elevating the sinus floor. *Compendium* 1994;15:698-704.
18. Albrektsson T, Zarb GA, Worthington P, Eriksson AR. The long-term efficacy of currently used dental implants. A review and proposed criteria of success. *Int J Oral Maxillofac Implants* 1986;1:11-25.
19. Adell R, Lekholm U, Grondahl K, Branemark, Lindstrom J, Jacobsson M. Reconstruction of severely resorbed edentulous maxillae using osseointegrated fixtures in immediate autogenous bone grafts. *Int J Oral Maxillofac Implants* 1990;5:233-46.
20. Nevins N, Langer B. The successful application of osseointegrated implants to the posterior jaw: A long-term retrospective study. *Int J Oral Maxillofac Implants* 1993;8:428-32.
21. Cawood JI, Howell RA. A classification of the edentulous jaws. *Int J Oral Maxillofac Implants* 1988;17:232-36.
22. Vercellotti T. Technological characteristics and clinical indications of piezoelectric bone surgery. *Minerva Stomatol* 2004;53:207-14.
23. Schlee, Markus, Steigmann, Marius Dr. medic stom, Bratu, Emanuel, Garg, Arun K. Piezosurgery: Basics and possibilities. *Implant Dentistry* Dec 2006;15(4):334-40.
24. Sohn DS. Piezoelectric ridge splitting. *Dent Success* 2003;11:1323-28.

## ABOUT THE AUTHORS

### Nettemu Sunil Kumar

Assistant Professor, Department of Periodontology and Oral Implantology, Faculty of Dentistry, Melaka-Manipal Medical College Jalan Batu Hampar, Bukit Baru, Melaka, Malaysia

### Nettem Sowmya (Corresponding Author)

Assistant Professor, Department of Periodontology and Oral Implantology, Faculty of Dentistry, Melaka-Manipal Medical College, Jalan Batu Hampar, Bukit Baru 75150, Melaka, Malaysia Phone: 60 0105092130, e-mail: drsowmyark@gmail.com